

## Olanzapine-associated Asymptomatic Eosinophilia: A Case Report

Olanzapine is a second-generation antipsychotic (atypical) drug that causes few extrapyramidal side effects. The common side effects of olanzapine are sedation and metabolic syndrome. In 2016, the US Food and Drug Administration reported a rare but severe olanzapine-associated skin reaction as a side effect – drug reaction with eosinophilia and systemic symptoms. We present a case of eosinophilia developed after olanzapine use. But our patient could tolerate the side effects and exhibited reduced psychotic symptoms.

### Case Report

A 35-year-old male patient with a history of moderate intellectual disability (full scale intelligence quotient = 52) and epilepsy. At his age of 11 years, he began experiencing generalized tonic-clonic seizures, which were satisfactorily controlled with anticonvulsants. He began to experience active psychotic symptoms at the age of 20 years. His psychiatric diagnosis was schizophrenia. His electroencephalography did not show epileptiform discharges, and no seizures when he had unstable psychotic symptoms. We only found diffuse cortical dysfunction in his follow-up electroencephalography. Therefore, we consider that the patient's psychotic symptoms were not related to epilepsy. With the use of risperidone, quetiapine, valproic acid, phenytoin, and clonazepam, he had remained stable and did basic self-care functions for the past decade.

At patient's first hospitalization at 35 years old, he presented himself with worsen psychotic symptoms, including auditory hallucinations with conversing and commanding content and multiple queer delusions. He thought that he was powerful and he had to save his mother. He claimed that his mother had been possessed by an evil spirit; he had thus enacted

aberrant behaviors toward her, including violence and attempted exorcism. After being switched from his previous antipsychotic drugs to olanzapine, he showed less self-talking and disorganized behaviors and reported fewer abnormal thoughts. He had increased interactions with other patients, and was willing to take part in group activities.

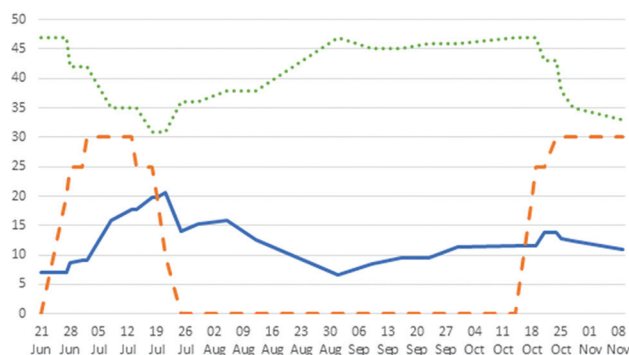
The patient's laboratory profile was evaluated for differential diagnosis on admission. There were no abnormal findings. For his sodium valproate use, we checked laboratory data after one week. His blood profile showed eosinophilia after he was started on olanzapine. His blood eosinophil level was increased from 9.0% (671.4 cells/ $\mu$ L) to 20.6% (1,437.88 cells/ $\mu$ L) in three weeks. White blood count was 6,980 cells/ $\mu$ L at first-time olanzapine use and 10,770 cells/ $\mu$ L at second-time challenge. Mild leukocytosis was improved after three months. But he had no other physical symptoms such as skin rash, lymphadenopathy, or abdominal symptoms. He denied histories of asthma, ectopic dermatitis, and all other inflammatory diseases. His blood antinuclear antibody level was 1: 80X. Cerebrospinal fluid findings were normal, and stool examination was negative for having both parasites and amoebae.

Because of the patient's long-term use of the same anticonvulsants with phenytoin and sodium valproate, we suspected that olanzapine was associating with his eosinophilia. Therefore, we discontinued his olanzapine, and his eosinophilia was subsequently improved. But his psychotic symptoms were recurred after discontinuation. The patient was readmitted to the inpatient unit for the treatment of psychotic symptoms two weeks after discharge. During the second hospitalization, we tried to treat him with nonolanzapine antipsychotics, including risperidone, amisulpride, and zotepine. But his psychotic symptoms were not improved.

To control the patient's refractory psychotic symptoms, we re-started olanzapine and closely monitored his physical condition and laboratory profile. He achieved remission of psychotic symptoms after we increased the olanzapine dosage to 30 mg/day.

As antipsychotic drug was shifted to olanzapine, the starting dose was 25 mg/day and was increased to 30 mg/day in 1 week. Psychotic symptoms much improved. The Positive Symptom Scale in the Positive and Negative Syndrome Scale showed decreased score from 47 to 31. As we discontinued olanzapine, eosinophil count was decreased and psychotic symptoms were increased. Then, we rechallenged with olanzapine, and the eosinophil level was maintained around 10%–15% (Figure 1).

In the following three years, his psychiatric symptoms were stabilized, and he had no physical complaints. But he continued to exhibit eosinophilia, but with a blood eosinophil level of < 15%.



**Figure 1.** The relationship between level of eosinophil count, dosage of olanzapine, and positive psychotic symptoms — Eosinophilia (%) — Olanzapine (mg), ..... PANSS, Positive Syndrome Scale. PANSS: Positive and Negative Syndrome Scale.

## Comment

Eosinophilia is defined as a peripheral eosinophil count exceeding 600 cells/ $\mu$ L. In hypereosinophilia, the eosinophil count is over 1,500 cells/ $\mu$ L [1].

Our patient's blood eosinophil count was increased rapidly during his hospitalization. Eosinophilia has various causes such as parasitic infection, atopic or allergic disease, malignancy, and other hematologic disorders [2]. We did serial examinations but got no specific results. We suspected that the asymptomatic eosinophilia was drug induced because he did not exhibit systemic discomfort [3]. He had used the same anticonvulsants for more than 10 years and recently switched antipsychotic drugs to olanzapine. Given the temporal coincidence, olanzapine is likely to be associated with this patient's asymptomatic eosinophilia.

Eosinophilia is a rare side effect of olanzapine. Studies have reported life-threatening cases of conditions including eosinophilic myocarditis [4] and pleuritis [5]. We also consider drug interaction that sodium valproate and olanzapine may be associated with severe hypersensitivity syndrome [6]. One case report has shown olanzapine-induced limb edema simulating episodic angioedema with eosinophilia [7]. Based on those case reports, immediate discontinuation of olanzapine is strongly recommended when eosinophilia occurs. Our patient experienced nearly no hypersensitive reaction despite using olanzapine for a second round. We believe that he had olanzapine-associated asymptomatic eosinophilia. Familiar phenomenon has been reported for clozapine use [8], but rarely been reported for olanzapine use.

The long-term consequences of asymptomatic eosinophilia remain unclear. Patients with asymptomatic drug-induced eosinophilia may not require treatment besides close monitoring. There is concern for eosinophil-induced organ damage, a markedly high level of eosinophilia (absolute eosinophil count > 100,000 cells/ $\mu$ L), or clinical evidence for leukostasis, and then corticosteroids should be given [9]. Therefore, we carefully monitored the patient's general condition to prevent target organ damage. On the basis of this experience, we recommend clinicians be aware of olanzapine-induced eosinophilia because it may be associated with severe consequences. (The institutional review board of Chung Shan Medical University Hospital approved this case report for publication (protocol number = CS1-20065, and date of approval = June 1, 2020) with the requirement of obtaining signed informed consent from the patient.)

## Financial Support and Sponsorship

Nil.

## Conflicts of Interest

The authors declare no conflicts of interest in writing this letter.

## References

1. Tournikioti K, Douzenis A, Antoniadou A, et al.: Eosinophilia associated with olanzapine. *J Clin Psychopharmacol* 2016; 36: 180-1.
2. Thomas B, Nutman MD: Evaluation and differential diagnosis of marked, persistent eosinophilia. *Immunol Allergy Clin North Am* 2007; 27: 529-49.
3. Ramírez E, Medrano-Casique N, Tong HY, et al.: Eosinophilic drug reactions detected by a prospective pharmacovigilance programme in a tertiary hospital. *Br J Clin Pharmacol* 2017; 83: 400-15.
4. Vang T, Rosenzweig M, Bruhn CH, et al.: Eosinophilic myocarditis during treatment with olanzapine – report of two possible cases. *BMC Psychiatry* 2016; 16: 70.
5. Evison M, Holme J, Alaloul M, et al.: Olanzapine-induced eosinophilic pleuritis. *Respir Med Case Rep* 2015; 14: 24-6.
6. Penchilaiya V, Kuppli PP, Preeti K, et al.: DRESS syndrome: addressing the drug hypersensitivity syndrome on combination of sodium valproate and olanzapine. *Asian J Psychiatr* 2017; 28: 175-6.
7. Honma M, Minami-Hori M, Tsuji H, et al.: Olanzapine-induced limb edema simulating episodic angioedema with eosinophilia. *J Dermatol* 2012; 39: 1105-6.
8. Wysokiński A, Kolińska J: Rapidly developing and self-limiting eosinophilia associated with clozapine. *Psychiatry Clin Neurosci* 2015; 69: 122.
9. Rauscher C, Freeman A: Drug-induced eosinophilia. *Allergy Asthma Proc* 2018; 39: 252-6.

Yueh-Pin Lin, M.D., Yu-Yu Tsai, M.D., Te-Jen Lai, M.D., Ph.D.\*

Department of Psychiatry, Chung Shan Medical University Hospital, Taichung, Taiwan

\*Corresponding author. No. 110, Section 1, Jianguo North Road, Taichung 402, Taiwan.  
E-mail: Te-Jen Lai <tejenlai@hotmail.com>

Received: Mar. 10, 2020 revised: Jun. 1, 2020 accepted: Jun. 1, 2020  
date published: Jun. 26, 2020

This is an open access journal, and articles are distributed under the terms of the Creative Commons Attribution-NonCommercial-ShareAlike 4.0 License, which allows others to remix, tweak, and build upon the work non-commercially, as long as appropriate credit is given and the new creations are licensed under the identical terms.

### Access this article online

#### Quick Response Code:



Website:  
www.e-tjp.org

DOI:  
10.4103/TPSY.TPSY\_18\_20

**How to cite this article:** Lin YP, Tsai YY, Lai TJ. Olanzapine-associated asymptomatic eosinophilia: A case report. *Taiwan J Psychiatry* 2020;34:98-9.

© 2020 Taiwanese Journal of Psychiatry (Taipei) | Published by Wolters Kluwer - Medknow